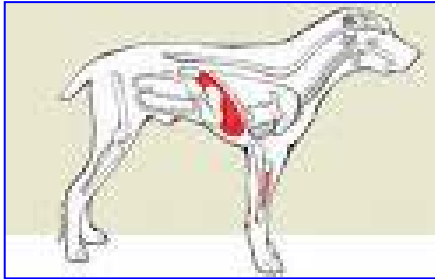


HEMANGIOMA & HEMANGIOSARCOMA

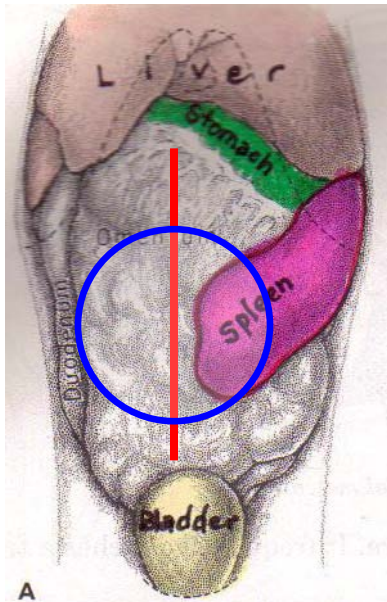
The spleen (in blue) is located inside the abdomen alongside the stomach, just behind the ribcage and the liver (in red).



Below is an x-ray of a dog with a tumor of the spleen. The red arrow to the left points to the liver. The blue one to the right points to the large, round tumor shape.

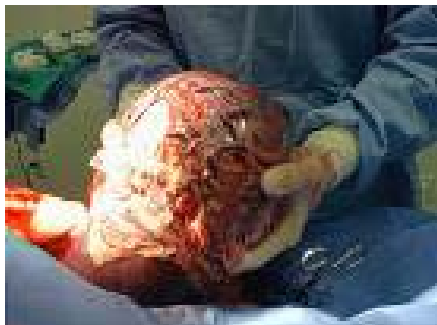

These tumors can become quite large before they are noticed. They frequently tear open and cause internal bleeding.

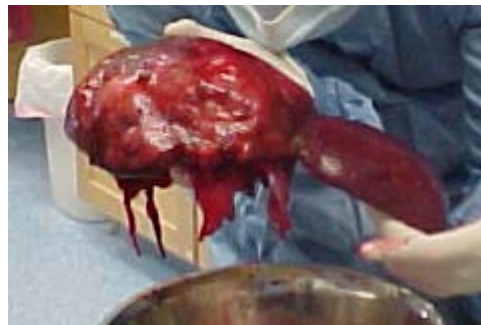

When this happens, the dog will get weak and pale.

When the pet is lying on its back and we make a surgical incision into the abdomen, the spleen should be laying toward the left side of the body. The red line indicates where we would make a surgical incision down the length of the abdomen, to remove the spleen. The blue circle represents the size and shape of the tumor on the spleen.



▲ This tumor probably weighs about 5 lbs. The largest one we've ever removed weighed 8 lbs!



◀ The tumor is the large blob on the left, while the right hand part of the spleen is still normal.